Prevalence and Length of the Anterior Loop of the Inferior Alveolar Nerve in Iranians

Maryam Rastegar Moghddam, DDS[1]
Zeinab Davoudmanesh, DDS[2,3]
Nasim Azizi, DDS[3]
Vahid Rakhshan, DDS[4]
Mahsa Shariati, DDS, MS[2]*

The anterior loop of the inferior alveolar nerve is a sensitive anatomical feature that should be taken into account during installation of dental implants anterior to the mental foramen. This study was conducted to explore the controversy regarding prevalence and length. A total of 452 mandible quadrants of 234 patients (age: 50.1 ± 13.3 years, 113 males, 121 females) were studied using cone-beam computerized tomography. After reconstructing axial, frontal, and sagittal slices, the region between the most anterior point on the mental foramen and the most anterior part of the mandibular nerve was inspected for signs of anterior loop presence. If positive, the length of the anterior loop was measured in mm as the distance between the anterior border of mental foramen and the anterior border of the loop. Prevalence and length of the anterior loop were compared statistically between sexes and age groups. The anterior loop was observed in 106 quadrants (23.5% of 451 quadrants) of 95 patients (40.6% of 234 patients), of whom 11 had bilateral anterior loops. Prevalences were similar in males (41%) and females (39%, chi-square $P = .791$). The mean anterior loop length was 2.77 ± 1.56 mm (95% CI: 2.5–3.1 mm), without significant sex (regression beta = −0.159, $P = .134$) or age (beta = −0.059, $P = .578$) differences. The anterior loop might exist in about 40% of patients, regardless of their gender. The mean safe anterior distance from the anterior loop is about 3 mm + (2.5–3.1 mm) = 5.5–6.1 mm, regardless of age.

Key Words: maxillofacial anatomy, dental implantation, iatrogenic damage, mental foramen, anterior loop of the inferior alveolar nerve

Downloaded from http://meridian.allenpress.com/doi/pdf/10.1563/aaid-joi-D-16-00212 by guest on 16 November 2021

INTRODUCTION

Almost between the roots of the premolars, the inferior alveolar nerve furcates in two branches: one is the incisive nerve, a continuation of the inferior alveolar nerve within the anterior section of mandible. The other one first goes up within the bone and then exits it into the soft tissue from the mental foramen. Therefore, as a landmark with numerous nerve fibers in vicinity, mental foramen marks a danger zone for inserting implants or performing other surgeries.[1–6] Regions anterior to the mental foramen are considered much safer because in these anterior areas, there is only the incisive canal down the mandible trunk. Nevertheless, in some cases, the second branch not only goes up to form the mental foramen and exit the bone; instead, it first continues forward, then curves up and backward, and then exits the bone. Such a case is called the anterior loop, and it has clinical implications: In its presence, regions immediately anterior to the mental foramen cannot be considered safe.[1–6] Therefore, implant installation or other selective surgeries in the interforaminal region might violate the anterior loop, disturbing chin and lower lip sensation.[2–6]

Strategies have been proposed to avoid these complications, such as keeping at least 5 mm away from the mental foramen.[5–8] In spite of the existence of such strategies, it is still better to know the accurate position of the anterior loop since this distance might differ in different individuals or ethnicities.[6] This cannot be done clinically, as probing cannot differentiate between the anterior loop and the incisive canal.[6,9] Two-dimensional radiographic methods cannot accurately identify the anterior loop.[10–12] Although 3D radiographic methods such as cone-beam computed tomography (CBCT) can help in identifying the anterior loop, these procedures cost patients' money and extra X-ray doses; many surgeons—especially the experienced ones—still use panoramic radiographs before implantation in the mandible.[2,5,13,14] Although this method accurately identifies the mental foramen,[14] it does not always visualize the anterior loop as does the CBCT.[5,6,10–12] Since common radiographic methods and clinical approaches cannot accurately identify the anterior loop, evaluating the prevalence of anterior loop and outlining an accurate, safe distance from the mental foramen in different ethnic groups is of clinical significance. Previous studies are highly controversial in terms of anterior loop length and even its existence.[3–6,15] For example, anterior loop prevalence has been reported as anywhere

[1] Private practice, Tehran, Iran.
[2] Craniomaxillofacial Surgery Research Center, Tehran University of Medical Sciences, Tehran, Iran.
[3] Craniomaxillofacial Research Center, Islamic Azad University, Tehran, Iran.
[4] Department of Dental Anatomy, Dental School, Azad University of Medical Sciences, Tehran, Iran.
* *Corresponding author,* e-mail: masha.shariati@gmail.com
DOI: 10.1563/aaid-joi-D-16-00212

TABLE 1

Anterior loop length in different study groups*

Groups	Mean	SD	Min	Q1	Med	Q3	Max	95% CI	
Sex									
Females	3.01	1.76	0.50	1.53	2.45	4.28	7.10	2.53	3.49
Males	2.53	1.29	0.10	1.70	2.40	3.10	6.70	2.17	2.88
Age (years)									
<30	2.98	1.63	0.50	1.60	3.10	3.80	6.00	2.20	3.77
30–39	2.99	1.87	0.70	2.00	2.45	3.78	7.10	2.11	3.86
40–49	2.52	1.46	0.10	1.45	2.40	3.28	5.30	1.90	3.14
50–59	2.83	1.55	1.00	1.50	2.40	3.35	6.50	2.08	3.57
≥60	2.64	1.37	0.90	1.80	2.20	3.00	6.40	2.07	3.20

*SD indicates standard deviation; Min, minimum; Q1, first quartile; Med, median; Q3, third quartile; Max, maximum; CI, confidence interval.

between 7% and 85.2%.[1,2,4–6,16–18] The average anterior loop length has been reported as 0.4 mm to 6 mm.[1–6,19,20] Moreover, there are no studies on Iranians. Therefore, we aimed to evaluate the prevalence of anterior loop and its length in an Iranian population. Research questions were the prevalence and length of anterior loop, as well as the existence of any potential associations between either of the variables anterior loop prevalence and its length with age and sex.

Material and Methods

More than 700 CBCT volumes were evaluated for eligibility. They were taken retrospectively for various clinical indications (eg, assessment of impacted teeth, pathologies, implant planning, or trauma) with a CBCT unit (NewTom VGi, Verona, Italy) in a private radiology center. No patients were radiographed because of this research, and patient information was handled anonymously. Since health or rights of patients were not harmed in any way by this retrospective research on anonymized data, the methodology was considered ethically safe and not violating any of the points in the 2013 Helsinki Declaration. Protocol ethics were approved by the Research Committee of Azad University. All available files were evaluated for the eligibility criteria. Inclusion criteria consisted of the following items: complete patient files and records, CBCT volumes and images of proper quality, and bilateral or unilateral anterior mandibles present to a minimum 2 cm distal to the mental foramen and up to the lower cortical border. Exclusion criteria were any defects or pathologies in the anterior mandible and/or around the mental foramen in CBCT volumes, or any systemic or local pathologies (determined from patients' records and histories) that can affect the pathway and position of the mandibular canal and mental foramen.[6]

After evaluation of the available CBCT volumes against the eligibility criteria, 452 CBCT quadrants of 234 different patients were selected. Of these 234 patients, 17 had unilateral mandibles available, while 217 had bilateral anterior mandibles. Of 234 patients, 113 were males and 121 were females. Their mean age was 50.1 ± 13.3 years (range: 18–84). The cases were categorized by gender and age.[6]

Measurements

A dentist with experience of using the CBCT device performed all the measurements using the CBCT unit's calibrated software (NNT, Version 4.5, NewTom). After reconstructing axial, frontal, and sagittal slices, two key anatomic landmarks were identified: (1) the most anterior point on the mental foramen and (2) the most anterior part of the mandibular nerve (defined as the most mesial area of the mental nerve just before a sudden constriction [when the incisive nerve is branching]). The region around and between these key landmarks was inspected for signs of anterior loop presence. In this case, the anterior border of the loop was determined. The length of the anterior loop was measured in mm as the distance between the anterior border of mental foramen and the anterior border of the loop.[6] All measurements were done only once and by the same observer.

Statistical analysis

Descriptive statistics were calculated for the prevalence of anterior loop and its length, in different groups (bilateral versus unilateral, in different sexes and in different ages). The patients were divided into 5 age groups: <30, 30–39, 40–49, 50–59, and ≥60. Before assessing the associations, the average of bilateral anterior loop lengths in patients having them was calculated. The used software was SPSS (Version 20, IBM, Armonk, NY). The associations between age and sex with the occurrence and length of anterior loop were evaluated using multiple regression and an independent-samples *t*-test. The level of significance was predetermined as 0.05.

Results

The anterior loop was observed in 106 quadrants (23.5% of 451 quadrants) and in 95 patients (40.6% of 234 patients). There were 11 instances of bilateral anterior loop occurrences (22 loops in 11 patients).

The anterior loop was observed in 47 females (39% of 121 females) and 46 males (41% of 113 males). The overall prevalence was 39.7% with no significant difference between the prevalence in two genders (chi-square $P = .791$). In the patients with anterior loops, the mean length of the anterior loop was 2.77 ± 1.56 mm (95% CI = 2.47–3.07, Table 1). The *t*-test did not detect a significant difference between the anterior loop lengths of two sexes ($P = .109$, Figure 1, Table 1). Moreover, according to the regression, there were no significant associations between the length of anterior loop and patients' age (beta = −0.059, $P = .578$) or gender (beta = −0.159, $P = .134$).

Discussion

The findings of this study indicated that anterior loop exists in about 50% of patients, with lengths about 2 to 3.5 mm, and without noticeable intersexual differences. Our findings were in in the middle of the range of anterior loop prevalences reported by some anatomical studies as zero[21] to some studies reporting a 88% to 100% prevalence of anterior

Downloaded from http://meridian.allenpress.com/doi/pdf/10.1563/aaid-joi-D-16-00212 by guest on 16 November 2021

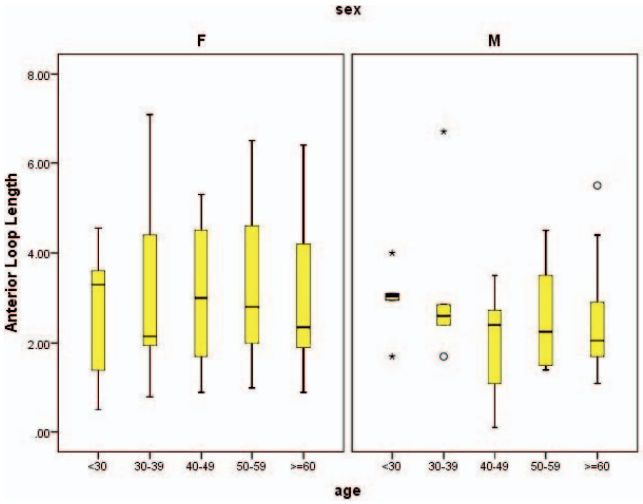

Figure 1. Box-plot of anterior loop lengths (mm) in different age groups and sexes.

loops[19,22] and in line with some other studies finding about 50% prevalence for anterior loop occurrence.[6,15,23–27] The controversies can be due to methodological differences and ethnical variations.[5] Different anatomical, radiographic, and combined approaches have been used to estimate the presence and length of the inferior alveolar nerve's anterior loop.[6,9,20,27] The use of digital 3D volumes is limited to recent few studies,[16–18,20] and many of these are limited to vertical cross sections only and printed on films,[16,17,20] which disallowed using digital features such as zooming as well as 3D construction. Few studies used digital rulers and other features of measuring software programs.[6,20] Radiographic methods relied conventionally on panoramic radiographs (if it can be detected) that have different extents of magnification throughout the image and might lead to inaccurate identification of the anterior loop length; this would depend on numerous factors such as the head posture, dental arch form, bite block location, radiograph units.[5,11,12,17,22,25] A recent study failed to find a significant difference between CBCT and panoramic method in terms of estimating the prevalence and length of anterior loop.[5] Modern 3D radiographic approaches consist of computerized tomography (CT) and cone-beam CT (CBCT). CT studies showed anterior loop prevalence such as about 7%,[16] 28.5%,[1] 34%,[17] 41.6%[2] (close to this study), 48%,[6] 48.8%,[5] 55%,[18] and 85.2%.[4] Although CT can have a higher resolution, its voxels are not squared cubes, which disallows oblique sections; this is not the case in CBCT. This, together with not using 3D constructions in some previous 3D digital studies, might be another reason for differences. Another reason could be that some studies subjectively determined a cut-off diameter for diagnosis of anterior loop from incisive canal,[6] which could reduce the observed prevalences. Some designs were direct identification of anterior loop on surgical patients,[15] which might be influenced by several factors.[6] Another methodological difference is definition of anterior loops; some cases not diagnosed as anterior loop in certain studies might be considered typical anterior loops in another study.[6,21]

The average anterior loop length is reported as 0.4 to 6 mm in the literature with maximum lengths up to 9 or even 11 mm.[1–6,19,20] In the present sample, the anterior loop had a length of about 2.5 to 3.1 mm, with a maximum length of 7.1 mm, which was very close to few studies reporting anterior loops of about 2.1 mm or 2.8 mm length.[1,5] Reasons for differences might be ethnic differences, as well as methodological dissimilarities including different proportions of males/females (women might have shorter loops), or different methods of calculating the averages (for example, in a study, anterior loop length was reported as 0.9 mm considering the nonexisting anterior loops as a length of zero, while it was reported about 3 mm after excluding patients not having anterior loops).[5,6] According to the present study, in most patients, implants should be placed at least about 3 mm distant from the mental foramen as a minimum safe distance. However, it should be noted that in a few cases, the anterior loop is much longer; without proper CBCT examination, a small but important chance of nerve injury (about 7%[28]) and sensory dysfunction would be anticipated, even after considering a minimum safe margin of 3 mm.[6,28] Our result was in contrast to some studies finding sexual differences in terms of anterior loop length[2,6] and its prevalence.[2] Some other studies found no sexual dimorphism in anterior loop length.[4] A reason for controversies might be methodological differences such as sample sizes and degrees of contrasts. Some studies reported rather noticeable clinical changes in anterior loop lengths by aging (eg, from 1.9 mm in people 20 to 40 years old, and 1.1 in those in their 60s to 80s).[4] However, the differences between age ranges were smaller in this study (from 3 mm in patients under 30 to 2.6 mm in those above 60), which again might be attributable to a population's inherent characteristics or criteria for anterior loop detection and measuring.

This study was limited by some factors. Although its sample size was one of the largest ones in the literature, it would be better to collect a larger sample size based on pilot studies. In addition, it was better to estimate the reliability of methods by re-evaluating some of the cases, preferably by a second observer or at least for a second time by the same observer. Moreover, interpretation of CBCT images might be affected by artifacts and voxel sizes. The external validity of the findings was reduced by using CBCT volumes that could not be generalized to anatomical situations. Moreover, the results could not reflect on the Iranian ethnicity, as the CBCT volumes were taken from only one center. These were, however, the limitations of all previous studies.

Conclusions

Within the limitations of this study, it was concluded that the anterior loop might exist in about 40% of Iranian patients, regardless of their gender. In the 60% of patients having anterior loops, the mean safe anterior distance from the mental foramen and/or anterior loop (indicated by the 95% CI for the anterior loop length) is about 3 mm plus 2.5 to 3.1 mm (= 5.5–6.1 mm). Changes in this distance with aging were not noticeable either statistically or clinically.

Downloaded from http://meridian.allenpress.com/doi/pdf/10.1563/aaid-joi-D-16-00212 by guest on 16 November 2021

Abbreviations

CBCT: cone-beam computerized tomography
CT: computerized tomography

Acknowledgments

Authors wish to thank Dr Mehralizadeh for instructing the thesis. MRM searched the literature, performed the measurements, and collected the data. ZD, NA, and MS searched the literature. VR searched the literature, designed and performed the analyses, drafted/revised/submitted the article, and responded to reviewers.

Notes

The authors declare no conflict of interest. The study was self-funded by the authors.

References

1. Sahman H, Sisman Y. Anterior loop of the inferior alveolar canal: a cone-beam computerized tomography study of 494 cases. *J Oral Implantol*. 2016;42:333–336.

2. do Nascimento EHL, dos Anjos Pontual ML, dos Anjos Pontual A, et al. Assessment of the anterior loop of the mandibular canal: a study using cone-beam computed tomography. *Imaging Sci Dent*. 2016;46:69–75.

3. Chen Z, Chen D, Tang L, Wang F. Relationship between the position of the mental foramen and the anterior loop of the inferior alveolar nerve as determined by cone beam computed tomography combined with mimics. *J Comput Assist Tomogr*. 2015;39:86–93.

4. Lu CI, Won J, Al-Ardah A, Santana R, Rice D, Lozada J. Assessment of the anterior loop of the mental nerve using cone beam computerized tomography scan. *J Oral Implantol*. 2015;41:632–639.

5. Vujanovic-Eskenazi A, Valero-James J-M, Sánchez-Garcés M-A, Gay-Escoda C. A retrospective radiographic evaluation of the anterior loop of the mental nerve: comparison between panoramic radiography and cone beam computerized tomography. *Medicina Oral, Patología Oral y Cirugía Bucal*. 2015;20:e239–e245.

6. Apostolakis D, Brown JE. The anterior loop of the inferior alveolar nerve: prevalence, measurement of its length and a recommendation for interforaminal implant installation based on cone beam CT imaging. *Clin Oral Implants Res*. 2012;23:1022–1030.

7. Hunt DR, Jovanovic SA. Autogenous bone harvesting: a chin graft technique for particulate and monocortical bone blocks. *Int J Periodontics Restorative Dent*. 1999;19:165–173.

8. Nobel Biocare A. *Surgical Procedure Manual*. Göteborg, Sweden: Brånemark System; 1992.

9. Greenstein G, Tarnow D. The mental foramen and nerve: clinical and anatomical factors related to dental implant placement: a literature review. *J Periodontol*. 2006;77:1933–1943.

10. Mraiwa N, Jacobs R, Moerman P, Lambrichts I, van Steenberghe D, Quirynen M. Presence and course of the incisive canal in the human mandibular interforaminal region: two-dimensional imaging versus anatomical observations. *Surg Radiol Anat*. 2003;25:416–423.

11. Jacobs R, Mraiwa N, Van Steenberghe D, Sanderink G, Quirynen M. Appearance of the mandibular incisive canal on panoramic radiographs. *Surg Radiol Anat*. 2004;26:329–333.

12. Ngeow WC, Dionysius DD, Ishak H, Nambiar P. A radiographic study on the visualization of the anterior loop in dentate subjects of different age groups. *J Oral Sci*. 2009;51:231–237.

13. Zitzmann NU, Margolin MD, Filippi A, Weiger R, Krastl G. Patient assessment and diagnosis in implant treatment. *Aust Dent J*. 2008;53(suppl 1):S3–10.

14. Vazquez L, Saulacic N, Belser U, Bernard JP. Efficacy of panoramic radiographs in the preoperative planning of posterior mandibular implants: a prospective clinical study of 1527 consecutively treated patients. *Clin Oral Implants Res*. 2008;19:81–85.

15. Rosenquist B. Is there an anterior loop of the inferior alveolar nerve? *Int J Periodontics Restorative Dent*. 1996;16:40–45.

16. Jacobs R, Mraiwa N, VanSteenberghe D, Gijbels F, Quirynen M. Appearance, location, course, and morphology of the mandibular incisive canal: an assessment on spiral CT scan. *Dentomaxillofac Radiol*. 2002;31:322–327.

17. Kaya Y, Sencimen M, Sahin S, Okcu KM, Doan N, Bahcecitapar M. Retrospective radiographic evaluation of the anterior loop of the mental nerve: comparison between panoramic radiography and spiral computerized tomography. *Int J Oral Maxillofac Implants*. 2008;23:919–925.

18. Watanabe H, Abdul MM, Kurabayashi T, Aoki H. Mandible size and morphology determined with CT on a premise of dental implant operation. *Surg Radiol Anat*. 2010;32:343–349.

19. Neiva RF, Gapski R, Wang H-L. Morphometric analysis of implant-related anatomy in Caucasian skulls. *J Periodontol*. 2004;75:1061–1067.

20. Uchida Y, Noguchi N, Goto M, et al. Measurement of anterior loop length for the mandibular canal and diameter of the mandibular incisive canal to avoid nerve damage when installing endosseous implants in the interforaminal region: a second attempt introducing cone beam computed tomography. *J Oral Maxillofac Surg*. 2009;67:744–750.

21. Kieser J, Kuzmanovic D, Payne A, Dennison J, Herbison P. Patterns of emergence of the human mental nerve. *Arch Oral Biol*. 2002;47:743–747.

22. Arzouman MJ, Otis L, Kipnis V, Levine D. Observations of the anterior loop of the inferior alveolar canal. *Int J Oral Maxillofac Implants*. 1993;8:295–300.

23. Bavitz JB, Harn SD, Hansen CA, Lang M. An anatomical study of mental neurovascular bundle-implant relationships. *Int J Oral Maxillofac Implants*. 1993;8:563–567.

24. Solar P, Ulm C, Frey G, Matejka M. A Classification of the intraosseous paths of the mental nerve. *Int J Oral Maxillofac Implants*. 1994;9:339.

25. Kuzmanovic DV, Payne AG, Kieser JA, Dias GJ. Anterior loop of the mental nerve: a morphological and radiographic study. *Clin Oral Implants Res*. 2003;14:464–471.

26. Hu K-S, Yun H-S, Hur M-S, Kwon H-J, Abe S, Kim H-J. Branching patterns and intraosseous course of the mental nerve. *J Oral Maxillofac Surg*. 2007;65:2288–2294.

27. Uchida Y, Yamashita Y, Goto M, Hanihara T. Measurement of anterior loop length for the mandibular canal and diameter of the mandibular incisive canal to avoid nerve damage when installing endosseous implants in the interforaminal region. *J Oral Maxillofac Surg*. 2007;65:1772–1729.

28. Wismeijer Dv, Van Waas M, Vermeeren J, Kalk W. Patients' perception of sensory disturbances of the mental nerve before and after implant surgery: a prospective study of 110 patients. *Br J Oral Maxillofac Surg*. 1997;35:254–259.

Downloaded from http://meridian.allenpress.com/doi/pdf/10.1563/aaid-joi-D-16-00212 by guest on 16 November 2021

Erratum

In the 43(5) issue of *Journal of Implantology*, the article titled, "Prevalence and Length of Anterior Loop of the Inferior Alveolar Nerve in Iranians" (Moghaddam et al, 2017;333–336) was published with a typographical error in one of the author names. The correct spelling of the first author's name is Maryam Rastegar Moghaddam.

Downloaded from http://meridian.allenpress.com/doi/pdf/10.1563/aaid-joi-D-16-00212 by guest on 16 November 2021

DOI: 10.1563/aaid-joi-D-18-Erratum-44.3